



Brief Communication

Near-total absence of REM sleep co-occurring with normal cognition: an update of the 1984 paper



Efrat Magidov^{a,b}, Hanna Hayat^a, Omer Sharon^a, Fani Andelman^c, Shlomit Katzav^d, Peretz Lavie^e, Riva Tauman^d, Yuval Nir^{a,b,f,*}

^a Department of Physiology and Pharmacology, Sackler School of Medicine, Tel Aviv University, Tel Aviv, Israel

^b Sagol School of Neuroscience, Tel Aviv University, Tel Aviv, Israel

^c Functional Neurosurgery Unit, Tel Aviv Sourasky Medical Center, Tel Aviv, Israel

^d Sleep Disorders Center, Tel Aviv Sourasky Medical Center, Tel Aviv, Israel

^e The Ruth and Bruce Rappaport Faculty of Medicine, Technion-Israel Institute of Technology, Haifa, Israel

^f Functional Neurophysiology and Sleep Research Laboratory, Tel-Aviv Sourasky Medical Center, 64239 Tel-Aviv, Israel

ARTICLE INFO

Article history:

Received 14 June 2018

Received in revised form

13 August 2018

Accepted 10 September 2018

Available online 19 September 2018

ABSTRACT

Background: REM sleep (REMS) is considered vital for supporting well-being and normal cognition. However, it remains unclear if and how decreases in REMS impair cognitive abilities. Rare case studies of patients with REMS abolishment due to pontine lesions remain sporadic, and formal evaluation of cognitive status is lacking. In 1984, Lavie and colleagues described the case of Y.C. – a man with a pontine lesion and near-total absence of REMS who led a normal life. Here, we set out to re-evaluate this individual's REMS status 30 years after the original report, and formally assess his cognitive abilities.

Methods: Four whole-night polysomnographic sleep recordings were conducted to evaluate sleep architecture. Sleep scoring was performed according to the American Academy of Sleep Medicine (AASM) guidelines. Cranial Computed Tomography (CT) imaging was performed, as well as formal neuropsychological testing to evaluate cognitive functions.

Results: Y.C. averaged 4.5% of sleep time in REMS, corresponding to the 0.055 percentile of normal values for his age. Furthermore, residual REMS episodes were short and only occurred towards the end of the night. CT imaging revealed damage and metallic fragments in pons, cerebellum, and thalamus. Neuropsychological evaluation demonstrated average to high-average cognitive skills, normal memory, and motor difficulties including speech and left hand dyspraxia.

Conclusions: To our knowledge, this is the only case where REMS loss resulting from pontine lesion was re-evaluated after many years. We find a near-total absence of REMS with no signs of significant compensation throughout adult life, along with normal cognitive status. The results provide a unique perspective on the ongoing debate regarding the functional role of REMS in supporting cognition.

© 2018 Elsevier B.V. All rights reserved.

1. Introduction

Rapid Eye Movement Sleep (REMS) makes up about 20% of sleep time in adult humans. This sleep stage is homeostatically regulated such that selective REMS deprivation (REMD) results in "REM sleep pressure" manifested as a rebound in amount of REMS on post-deprivation recovery nights [1,2]. Research on the functional role of REMS began in the 1960s, when studies found that acute

selective REMD in humans led to anxiety and cognitive deficits [3]. Subsequent research established that prolonged REMD in rodents leads to weight loss, skin lesions, elevated heart rate, deficits in thermoregulation, and eventually death [4], supporting the notion that REMS is biologically necessary. More recently, a wealth of studies demonstrated that REMD impaired declarative, procedural and emotional memories [5,6], suggesting that REMS plays a role in supporting normal cognitive function.

However, the view that REMS is important for well-being and cognition has been challenged. In REMD studies, multiple awakenings involve stress that in itself causes physiological dysfunction and deteriorates memory [7]. A recent study reports that fur seals

* Corresponding author. Department of Physiology and Pharmacology, Sackler School of Medicine, Tel Aviv University, Tel Aviv, Israel.

E-mail address: ynir@post.tau.ac.il (Y. Nir).

have no or little REM sleep when they stay in water for days or weeks, with minimal or no subsequent REMS rebound, and no observed effects on their health [8]. Moreover, drug-induced suppression of REMS (a common consequence of antidepressants) does not impair cognition [9,10]. Another line of evidence against a role for REMS in cognition comes from case studies of patients with REM abolishment caused by pontine lesions. Although many of these cases result in a condition termed "locked-in" syndrome, there are some rare examples of people who apparently maintained normal lives despite the REMS loss [11]. In 1984, Lavie and colleagues described the rare case of Y.C. [12] – a man injured at age 20 during military service by shrapnel fragments. In the original study (when Y.C. was 33 years old) REMS was nearly completely absent. Neurological examination, brain imaging, and brainstem auditory evoked responses revealed a lesion at the mid-pontine level, in line with the pons considered as the necessary and sufficient generator of REMS [13]. During the original study, Y.C. led a normal life and graduated from law school. Here, nearly 35 years later, we set out to conduct a follow-up study (Y.C. is now 68 years old) to test whether REMS is still nearly entirely absent, and evaluate his cognitive status.

2. Methods

The study was approved by the Medical Institutional Review Board at the Tel-Aviv Sourasky Medical Center (TASMC), and Y.C. provided written informed consent to participate. Y.C. arrived at the TASMC sleep laboratory for four whole-night sleep studies (three of which were consecutive). Polysomnography (PSG) was performed using a commercially available system (Embla N7000; Embla Systems, Broomfield, CO) with whole-night presence of a sleep technician. Bilateral electrooculogram (EOG), eight channels of electroencephalogram (EEG), as well as chin and anterior tibial electromyograms (EMGs) were monitored. Chest and abdominal wall movement were examined with respiratory impedance plethysmography, and heart rate was monitored by electrocardiography. Air flow was measured by end-tidal capnography, which also provided breath-by-breath assessment of end-tidal carbon dioxide levels (PETCO₂; BCI SC-300, Menomonee Falls, WI), as well as by a nasal pressure transducer and an oronasal thermistor. Arterial oxygen saturation (SpO₂) was assessed by pulse oximetry (Nellcor N 100; Nellcor Inc., Hayward, CA), with simultaneous recording of the pulse waveform. Digital time-synchronized video recording was performed. In all nights, sleep was terminated spontaneously upon awakening. PSG data were reviewed in detail by three experienced sleep scorers supervised by an AASM board-certified sleep medicine physician. Sleep scoring was performed manually by visually inspecting 30-second PSG epochs according to AASM guidelines [14]. EMG and slow wave activity (SWA) were quantified (Fig. 1C–D) using custom-written Matlab scripts (The MathWorks): the root mean square (RMS) of the EMG signal, as well as power in 0.75–4.5 Hz of the central scalp EEG were computed in 30s intervals and divided according to sleep scoring labels. Movement artifacts (RMS EMG > 100 μ V) were discarded. SWA dynamics were estimated by dividing NREM intervals in each night separately into five bins. Cognitive evaluation was performed by an expert neuropsychologist (F.A.), using standard neuropsychological tests [15]. Cranial Computed Tomography (CT) scan was carried out using Philips ICT 256 taking 3 mm axial sections.

3. Results

Y.C.'s sleep profile is summarized in Fig. 1A–B. Total recording time averaged 491.6 min and total sleep time averaged 363.5 min, reflecting an average sleep efficiency of 73.6%. Average sleep

latency was 23.9 min, and mean percentages of sleep stages were: wake after sleep onset (WASO) 13.0%, N1 7.2%, N2 67.3%, N3 21.0%, and REMS 4.5% (range 0%–10.3%). This mean REMS rate is similar to the original findings at age 33, as well as significantly lower than the normal percentage for his current age group ($\mu = 19.5\%$, $SD = 5.9$, $n = 690$, 0.055 percentile) [16]. Notably, other sleep parameters detailed above are normal for his age [16]. As was the case in the original study, in each of these nights REMS appeared towards the end of the sleep period, with a latency of over 180 min. As expected, EMG and SWA profiles (Fig. 1C–D) revealed that muscle tone was highest in wakefulness (W), decreased through N1–N2–N3, and low in residual REMS, whereas SWA was low in both W and residual REMS, and increased through N1–N2–N3. Of note, SWA dropped during sleep by $49.3 \pm 6.2\%$, and this decline was well fit by exponential dynamics ($R^2 = 0.9$). Thus, classical models of sleep homeostasis regulation based on EEG SWA [17] remained relevant despite absence of REMS. Since NREM sleep with low muscle tone has been suggested as a marker of REMS regulation [18], we specifically searched for intervals where lowest EMG and lowest SWA may overlap; however, such intervals were rare comprising $1.41 \pm 1\%$ of sleep time. Thus, analysis of EMG and SWA did not reveal signs of "hidden REMS", nor could we reveal bouts of increased levels or variability of heart rate.

The respiratory PSG measures revealed moderate obstructive sleep apnea (OSA). Loud snoring concomitant with respiratory effort was present throughout the entire sleep time. Mean Spo₂ was 91% (range: 91–92%) and Spo₂ nadir was 71%. Spo₂ less than 90% was measured in 13% of TST (range: 3–16%). Mean AHI was 15.5 (range: 10.4–19.5). EtCO₂ measurements were below 50 mmHg.

Brain CT (Fig. 1E) revealed several intracranial metallic fragments consistent with gunshot injury, including a small fragment in the left thalamus, a small fragment in the basal cistern adjacent to left pons, and a number of small fragments in the right cerebellar hemisphere. There is extensive cystic malacia involving the right cerebellar hemisphere with involvement of the brachium pontis, atrophy and loss of volume of the pons predominantly involving the dorsal and left aspects, as well as compensatory dilatation of the fourth ventricle, atrophy of the left cerebral peduncle, and atrophy of the left cerebellar hemisphere.

The cognitive evaluation (Table 1) revealed an average to high-average level of general intelligence, with verbal skills more developed than visuo-spatial abilities. Amnesic functions were normal, including long-term semantic memory as well as learning and retention of new material, verbal, and visual. Language fluency was in the normal range. No significant difficulties were noted on tests of visual perception and executive functions. Mild dysarthria and fluctuations in attention and concentration were observed during verbal tasks. Plegia of the right hand as well as significant apraxia and fine-motor discoordination of the left non-dominant hand were observed.

4. Discussion

Our present observations show that Y.C. still displays near-total absence of REMS 35 years after the original report, without any apparent compensation over the years. Moreover, even when REMS occurred, it did not follow normal sleep architecture characteristics. REMS did not appear at the end of well-defined sleep cycles, it tended to be very short in length, and emerged only towards later stages of the night. It is reasonable to assume that Y.C. has spent his entire adult life with near-total absence of REMS. Modern CT imaging confirmed the presence of pontine damage, which is likely to account for such REMS abnormalities.

REMS is associated with multiple physiological signatures including tonic EEG activation, skeletal muscle atonia, irregular

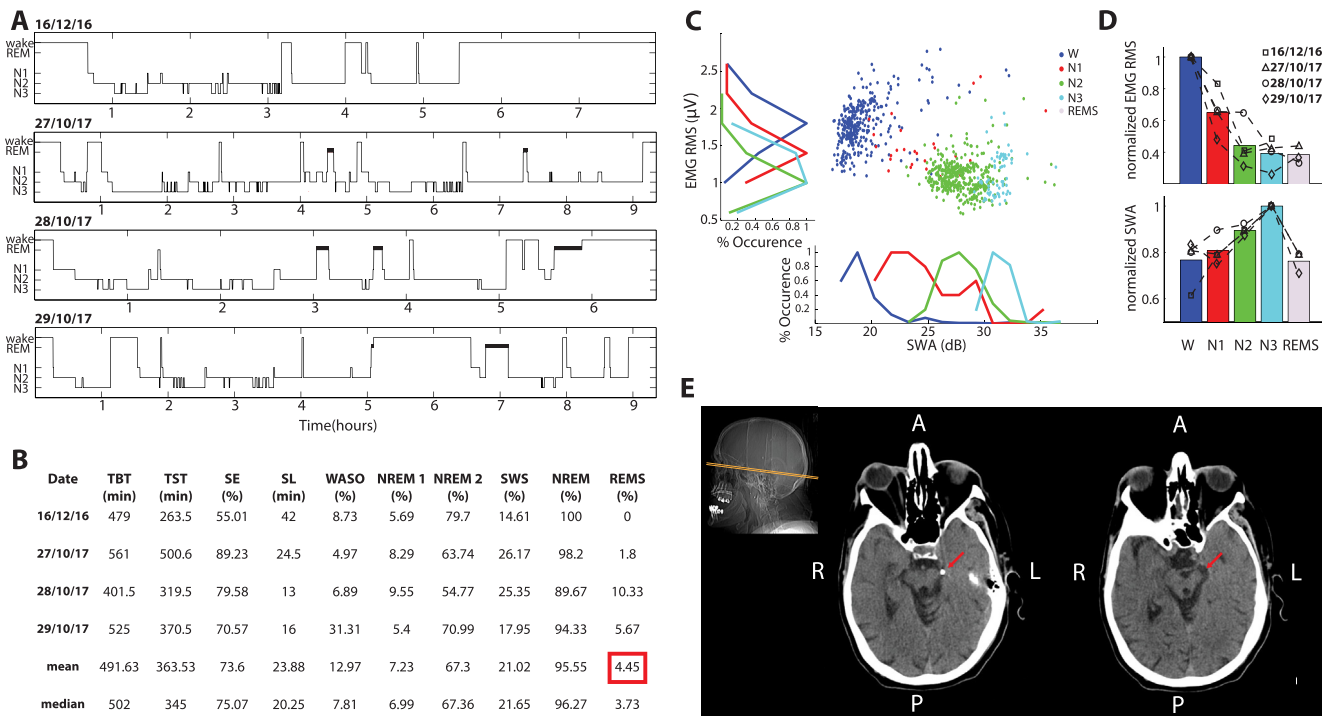


Fig. 1. Polysomnography and imaging results. (A) Sleep hypnograms for each of the four polysomnographic recordings. (B) Summary of sleep data for patient Y.C., mean % REMS is marked by red square (TBT: Total bed-time; TST: Total sleep-time; SE: Sleep efficiency; SL: Sleep latency; WASO: Wake after sleep-onset) (C) Scatter plot (dots) and projected distributions of EMG RMS (y-axis) vs. SWA (x-axis) in a representative session (16/12/16). Blue, W; Red, N1; Green, N2; Cyan, N3; Gray, REMS; Note the absence of intervals with low EMG and low SWA that would typically represent REMS periods on the lower left area of scatter plot. (D) Mean EMG RMS (top, normalized to W in each night), and SWA (bottom, normalized to N3 in each night). Colors as above. Black dashed lines show values in each sleep session (legend). (E) Cranial CT imaging (axial sections, inset) demonstrating a small metal fragment in the basal cistern adjacent to left pons (left image, red arrow) and left pontine atrophy (right image, red arrow). Anterior, A; Posterior, P; Left, L; Right, R.

Table 1

Neuropsychological evaluation. Absolute tests scores (middle column) and their relation to normative percentiles in that age group (right column). (SS: scale score).

Test	Score	Age percentile
Wechsler Adult Intelligence Scale (WAIS) III: Information	SS = 16	95%
Wechsler Adult Intelligence Scale (WAIS) III: Similarities	SS = 11	63%
Wechsler Adult Intelligence Scale (WAIS) III: Matrices	SS = 11	63%
Wechsler Memory Scale (WMS) III: Stories STM	SS = 13	84%
Wechsler Memory Scale (WMS) III: Stories LTM	SS = 12	75%
Wechsler Memory Scale (WMS) III: Faces	SS = 9	37%
F-A-S: verbal fluency	36	50%
Rey Auditory Verbal Learning Test (RAVLT): Learning	52	63%
Rey Auditory Verbal Learning Test (RAVLT): Retention	15	95%
Rey complex figure (RCF): copy	10	<5% (left hand dyspraxia)
Wisconsin Card Sorting Test (WCST): short version	2 categories	50%

breathing, increased heart rate, penile erections, as well as phasic REMs and muscle twitches. Could it be that Y.C.'s brain damage led to a near-total absence of some REMS features, while others were spared? While we cannot completely rule out this possibility, we could not find indications for bouts of peripheral markers of REMS such as increased heart rate or atonia. However, since Y.C. is diagnosed with OSA that entails recurrent autonomic arousals throughout the night, the interpretation of changes in heart rate and other markers of autonomic arousal as being related to REMS vs. OSA is difficult.

With regards to rapid eye movements, Y.C.'s neurological damage makes his EOG patterns atypical due to unconjugated gaze. To overcome this limitation, we instructed Y.C. to perform rapid horizontal saccades in wakefulness. Thus, any EOG patterns observed

during sleep that resembled these saccades were defined as rapid eye movements, so we believe the percent time spent in REMS reported here constitutes an upper bound. Notwithstanding, a follow up of the original study revealed that Y.C. had REM-like cycles in penile erections in spite of near total absence of REMS [19]. Therefore, it is impossible to completely rule out the possibility that some important features of REMS persist in Y.C. despite our inability to detect them with non-invasive measures.

Neuropsychological evaluation shows that significant disruption to REMS co-occurred with normal/above-average cognition and memory. Dysarthria and motor dysfunction of his upper extremities probably result from his subcortical pontine-cerebellar injury.

5. Conclusions

To our knowledge, this is the only case where REMS loss reported in early adulthood is re-confirmed in older age, and complemented by a neuropsychological examination of cognitive status. Since Y.C.'s near-total absence of REMS is not associated with robust effects on cognition or memory, his case challenges the views attributing an adaptive role for REMS in supporting cognition. In addition to their value for the sleep research community due to the rarity of this case, these findings add important and unique evidence to the long-going debate regarding the function of REMS.

Acknowledgements

We thank Y.C. for volunteering to participate in this research. We also thank Dr. Yoav Parag for interpreting the CT scan. The study was supported by the I-CORE Program of the Planning and Budgeting Committee and the Israel Science Foundation (Grant no. 51/11), and the Adelis Prize in Neuroscience.

Conflict of interest

The ICMJE Uniform Disclosure Form for Potential Conflicts of Interest associated with this article can be viewed by clicking on the following link: <https://doi.org/10.1016/j.sleep.2018.09.003>.

References

- [1] Endo T, Roth C, Landolt HP, et al. Selective REM sleep deprivation in humans: effects on sleep and sleep EEG. *Am J Physiol Regul Integr Comp Physiol* 1998;274(4):1186–94.
- [2] Ellman SJ, Spielman AJ, Luck D, et al. REM deprivation: a review. In: Ellman SJ, Antrobus JS, editors. *The mind in sleep*. 2nd ed. New York: John Wiley & Sons, Inc.; 1991. p. 329–69.
- [3] Dement W. The effect of dream deprivation. *Science* 1960;131(3415):1705–7.
- [4] Rechtschaffen A, Bergmann BM. Sleep deprivation in the rat: an update of the 1989 paper. *Sleep* 2002;25(1):18–24.
- [5] Rasch B, Born J. About sleep's role in memory. *Physiol Rev* 2013;93(2):681–766.
- [6] McCoy JG, Strecker RE. The cognitive cost of sleep lost. *Neurobiol Learn Mem* 2011;96(4):564–82.
- [7] Born J, Gais S. REM sleep deprivation: the wrong paradigm leading to wrong conclusions. *Behav Brain Sci* 2000;23(6):912–3.
- [8] Lyamin OI, Kosenko PO, Korneva SM, et al. Fur seals suppress REM sleep for very long periods without subsequent rebound. *Curr Biol* 2018;28(12):2000–5.
- [9] Schweitzer PK. Drugs that disturb sleep and wakefulness. In: Kryger MH, Roth T, Dement WC, editors. *Principles and practice of sleep medicine*. Amsterdam: Elsevier Saunders; 2000. p. 542–60.
- [10] Siegel JM. REM sleep: a biological and psychological paradox. *Sleep Med Rev* 2011;15(3):139–42.
- [11] Vertes RP, Eastman KE. The case against memory consolidation in REM sleep. *Behav Brain Sci* 2000;23(6):867–76.
- [12] Lavie P, Pratt H, Scharf B, et al. Localized pontine lesion: nearly absence of REM sleep. *Neurology* 1984;34(1):118–20.
- [13] Siegel JM. The neurobiology of sleep. *Semin Neurol* 2009;29(4):277–96.
- [14] Iber C, Ancoli-Israel S, Chesson A, et al. *The AASM manual for the scoring of sleep and associated events: rules, terminology and technical specifications*. 1st ed. Westchester, IL: American Academy of Sleep Medicine; 2007.
- [15] Lezak M, Howieson D, Bigler E, et al. *Neuropsychological assessment*. 5th ed. Oxford University Press; 2012.
- [16] Redline S, Kirchner HL, Quan SF, et al. The effects of age, sex, ethnicity, and sleep-disordered breathing on sleep architecture. *Arch Intern Med* 2004;164(4):406–18.
- [17] Achermann P, Dijk DJ, Brunner DP, et al. A model of human sleep homeostasis based on EEG slow-wave activity: quantitative comparison of data and simulations. *Brain Res Bull* 1993;31(1–2):97–113.
- [18] Tinguely G, Huber R, Borbély AA, et al. Non-rapid eye movement sleep with low muscle tone as a marker of rapid eye movement sleep regulation. *BMC Neurosci* 2006;7(1):2–10.
- [19] Lavie P. Penile erections in a patient with nearly total absence of REM: a follow-up study. *Sleep* 1990;13(3):276–8.